



**ESENTING CLINICAL SIGNS**

History: Grade 3-4/6 murmur. Congested, coughing, decreased energy. Increased breathing sounds bilaterally. Started on antibiotics.

DATE

10/25/21

**ECHOCARDIOGRAPHIC FINDINGS**

2D, M-mode, and Doppler study.

PERFORMED BY:

Kim Liedberg

Left atrial size is normal. The mitral valve appears normal, though trace mitral regurgitation is present. Left ventricular wall thickness is normal. Left ventricular internal dimensions are normal. Left ventricular systolic function is hyperdynamic. The aorta and aortic valve are normal. Right atrial and right ventricular dimensions are normal. The tricuspid valve is normal. The pulmonary artery and pulmonic valve are normal. No pericardial effusion or cardiac masses are seen.

INTERPRETED BY

Keith Blass, DVM,  
MS, DACVIM  
(Cardiology)

LA - 12.0 mm  
IVSd - 3.8 mm  
LVPWd - 3.9 mm  
LVIDd - 10.2 mm  
LVIDs - 4.3 mm  
FS - 57.8%  
LVOT - 1.00 m/s  
RVOT - 0.91 m/s

PATIENT

Lacey Fakiroglou

**ASSESSMENT/RECOMMENDATIONS**

SPECIES

Normal echocardiogram

Feline

This examination demonstrates no evidence of structural heart disease, as trace mitral regurgitation can be considered a normal physiologic variant. While a definitive reason for Lacey's murmur was not identified, it's likely that her murmur is functional/innocent in nature, as no flow abnormalities that could result in the development of a pathologic murmur were appreciated in the image set.

BREED

DLH

No reason for Lacey's decreased energy, congestion, and coughing is appreciated in the image set, and thoracic radiographs are recommended for further evaluation.

SEX

FS

No therapy is recommended based on this exam.

AGE

A recheck echocardiogram is recommended if the characteristics of Lacey's murmur change, or if other new physical exam and/or clinical abnormalities suggestive of cardiac dysfunction develop.

12 y

WEIGHT

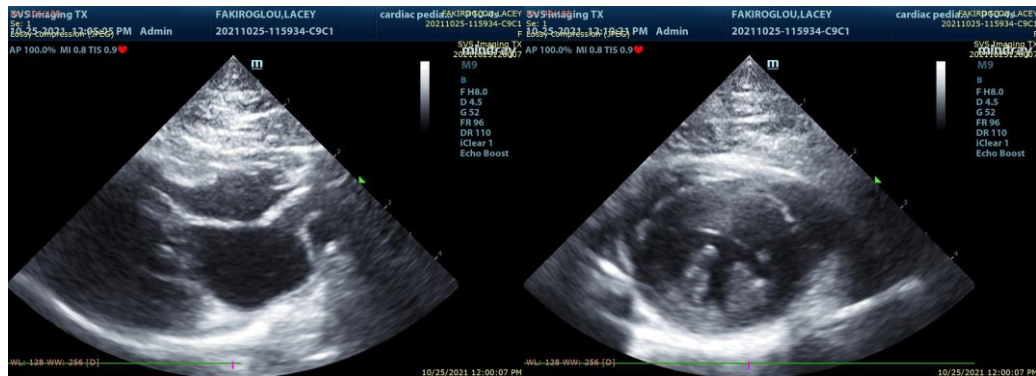
13.6 lb

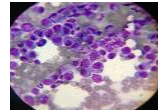
HOSPITAL NAME

New Berling AH

REFERRING VET

Dr. Sobon





**DATE**

10/25/21

The information and recommendations provided are based on the images presented by the referring veterinarian. No evaluation can be communicated regarding pathology that was not visible in the image/video clips provided.

Thank you for this referral. If the clinical or image interpretation does not parallel your findings or if I can be of any further assistance please contact me.

**PERFORMED BY:**

Kim Liedberg

**Keith Blass, DVM, MS, DACVIM (Cardiology)**

KeithBlass@gmail.com

631-804-5754

**INTERPRETED BY**

Keith Blass, DVM,  
MS, DACVIM  
(Cardiology)

**PATIENT**

Lacey Fakiroglou

**SPECIES**

Feline

**BREED**

DLH

**SEX**

FS

**AGE**

12 y

**WEIGHT**

13.6 lb

**HOSPITAL NAME**

New Berling AH

**REFERRING VET**

Dr. Sobon